

Research Article

Advances in Clinical Endocrinology and Metabolism

Active Surveillance of Indeterminate Thyroid Nodules: Beyond Cytological Diagnosis Ultrasound Evaluation and Molecular Analysis

Giusti M^{1,2*}, Santamarena G¹, Gay S¹, Mittica M¹, Zupo S³, Massa B⁴ and Monti E^{2,5}

¹Endocrine Unit, Policlinico San Martino Hospital, Italy

²Department of Internal Medicine and Medical Specialties, University of Genova, Italy

³Molecular Diagnostic Unit, Policlinico San Martino Hospital, Italy

⁴Cytopathology and Pathology Unit, Policlinico San Martino Hospital, Italy

⁵Thyroid GIP, Head and Neck Disease Management Team, Policlinico San Martino Hospital, Italy

***Correspondence:** Massimo Giusti, Department of Internal Medicine and Medical Specialties, University of Genova Viale Benedetto XV, No. 6 I-16100 Genoa, Italy, Tel: 39-010-3537953; Fax: 39-010-3538977; E-mail: omsv1416@gmail.com

Received date: July 27, 2019; Accepted date: Oct 30, 2019; Published date: Nov 4, 2019

Abstract

Background: Approximately 25% of nodules are classified as indeterminate after Fine-Needle Aspiration Biopsy (FNAB). Strategies for stratifying nodules according to risk are now needed in order to reduce unnecessary thyroid surgery. The aim of the study was to report the results of active surveillance in Thy 3 nodules, according to the British Thyroid Association, in which thyroidectomy was refused or postponed.

Methods: Eighty-seven nodules with indeterminate thyroid cytology underwent active surveillance. Active surveillance includes: calcitonin and thyroid blood tests, neck Ultrasonography (US), Elastasonography (USE), Contrast-Enhanced US (CEUS), mutation analysis and a 2nd FNAB. A 36-month period of active surveillance is scheduled.

Results: The 2nd FNAB resulted in down-classification to Thy 2, confirmation of Thy 3 category and subclasses - with changes in Thy 3 subclasses (6%) - and non-diagnostic information in 51%, 30% and 13% of cases, respectively. No upgrade of Thy category was observed when a further FNAB was performed during the observation period. US score and maximal nodule diameter did not change significantly from the baseline to the last examination. When surgery was performed during the observation period, malignancy was found in 17% of nodules. US score and CEUS indexes were significantly related to thyroperoxidase antibody positivity and US score, respectively.

Conclusions: Our prospective study suggests that active surveillance can be proposed for patients with indeterminate cytology and no other risk factors. Down-classification to Thy 2 is frequent when further information and material are collected for the pathologist. Simple changes in nodule diameter do not warrant surgery. However, more data are needed.

Keywords: Indeterminate thyroid nodules, Neck sonography, Active surveillance, Outcome

Abbreviations: FNAB: Fine-Needle Aspiration Biopsy; US: Neck Ultrasonography; USE: Elastasonography; CEUS: Contrast-Enhanced US; BTA: British Thyroid Association; AUS/FLUS: Atypia of Indeterminate Significance/Follicular Lesion of Indeterminate Significance; FN/SFN: Follicular Neoplasm/Suspicious for Follicular Neoplasm; BSRTC: Bethesda System for Reporting Thyroid Cytopathology

Introduction

The percentage of malignancy of indeterminate lesions varies, but is estimated at around 25% of cases [1,2]. Molecular biology, Ultrasound (US), Elasto-Ultrasonography (USE), Contrast-Enhancement Ultrasonography (CEUS) and functional and molecular imaging are currently taken into consideration [3,4] in order to reduce the number of unnecessary thyroidectomies, which are carried out if surgery is undertaken for definitive risk stratification. Surgery is still regarded as the first choice in follicular neoplasms, and is taken into consideration when the repetition of Fine-Needle Aspiration Biopsy (FNAB) confirms the diagnosis of indeterminate lesion with atypical features [5]. This choice is motivated by the fact that data on the behavior and follow-up of indeterminate cytology nodules that do not undergo surgery have so far been unavailable. Surgery is always indispensable when molecular biology is highly suggestive of the presence of a malignant neoplasm in this type of nodule [4,6,7]. In order to reduce the number of surgical procedures, observational studies have been carried out, and cytologic and ultrasonographic observation has been proposed as a pragmatic means of reducing inappropriate surgery in patients with indeterminate lesions and negative molecular biology, but who may have a malignant thyroid neoplasm [8-10]. The patient's acceptance of observation, as opposed to surgery, seems to be good, and is supported above all by the evaluation of molecular biology [11].

Recently, we evaluated the diagnostic power of US, USE and CEUS in the pre-surgical investigation of indeterminate nodules. Our nodule analysis was carried out in accordance with both the 2007 British Thyroid Association (BTA) classification system, and the new 2014 BTA classification system, in subjects in whom the cytological report was correlated with the histology report [3,12]. The availability of these indexes allowed us to offer patients with normal calcitonin levels and an indeterminate Thy 3 lesion or its sub-classifications an alternative to surgery.

Here, we describe our experience in the observation of nodules with indeterminate cytology and BRAF-negative molecular biology, and US, USE, and CEUS assessments that do not suggest surgical initiation. Surgery was postponed, in agreement with the patient, when adherence to a strict observational program was ensured; cytological examination was also repeated during the course of this program.

Materials and Methods

Patients

The study involved patients referred to the Endocrine Unit of San Martino Polyclinic Hospital in Genoa for FNAB of a thyroid nodule (n=1211) from January 2015 to December 2018. FNAB was performed according to the indications reported in the guidelines of the American Thyroid Association [13]. All patients (n=109) with indeterminate cytology on FNAB examination were asked to participate in this prospective observational study. Six patients with indeterminate thyroid nodules did not provide written informed consent and were excluded from the study. Another six patients withdrew their initial consent, preferring to continue their follow-up in other centres. Six patients were excluded from the study before the first 6-month evaluation, either because they subsequently decided to undergo surgery (n=2; histology: follicular adenomas; n=1 nodular hyperplasia) or because we recommended surgery on the grounds of BRAF-positive mutation (n=1 histology: papillary thyroid carcinoma; PTC), worsened compressive symptoms (n=1 histology: follicular carcinoma; FTC), or a US score strongly suspicious for malignancy (n=1 histology: follicular variant of PTC; FvPTC). Four patients were excluded from the analysis because they had not completed 6 months of follow-up at the time when this paper was written. The study group therefore consisted of 87 patients (20 males and 67 females) aged 52.5 years on average (± 13.8 years; \pm SD). Thirteen patients (15%) had a uninodular goiter while in the remainder (n=64; 85%) the indeterminate nodule was located within a Multinodular Goiter (MNG). Hashimoto's thyroiditis was diagnosed in 16 patients. At the beginning of the study, 16 patients (18%) were on Levo-thyroxine (L-T4) in order to lower TSH levels. Four patients (5%) were on low-dosage methimazole for pre-toxic/toxic MNG. All patients were informed that the current Italian guidelines [5] suggest surgery as the final referral for patients with indeterminate nodular thyroid lesions. Patients were informed of the institutional percentages of malignancy on histology in patients undergoing surgery for indeterminate lesions [3,12]. The study was discussed by the multidisciplinary thyroid team (Gruppo Interdisciplinare Patologia Tiroidea) and each patient's entry to the study was approved. Patients provided written informed consent.

Protocol

After an initial finding of an indeterminate thyroid lesion on FNAB, patients were considered eligible for this observational prospective study. Patients was asked to have a blood test to evaluate their thyroid function (f-T4,

TSH) and thyroid autoimmunity, and to confirm normal calcitonin levels. Separate written consent was requested in order to utilize a cytological slide for BRAF and RAS mutational analysis. A new US was performed to evaluate nodular dimension and to stratify the sonographic risk of malignancy according to the score previously reported [3]. Elastosonography (USE) and Contrast-Enhanced US (CEUS) examinations were also performed to evaluate nodular strain and vascularity. CEUS was performed only in patients who provided specific informed consent to contrast injection. Thereafter, a second FNAB was performed in all selected nodules, to exclude a cytological up-grade. All patients were informed that by signing the consent form they agreed to undergo further examinations 6, 12, 24 and 36 months after entry to the study, and a further FNAB 1-2 years later. Withdrawal from the study was envisioned in the following cases: patient decision, compressive symptoms related to nodular growth, objective increase of >50% in the maximal diameter of the nodule, doubling of initial US risk score, up-grade on the further FNAB, end of the 36-month observation period. Patients were informed that, after the 36-month period, further examinations could be performed at the Endocrine Unit and that they would be managed according to good clinical practice.

Blood tests

Blood samples were analysed by means of ultra-sensitive chemiluminescence immunoassay (Roche Diagnostics, Mannheim, Germany) to evaluate TSH and f-T4 (normal ranges 0.3-4.2 mU/L for TSH, 15.4-28.3 pmol/L for f-T4). The DiaSorin assay (Saluggia, Italy) was used to detect Thyroperoxidase Antibodies (TPOAb), and concentrations <100 U/mL were considered negative. For serum calcitonin, a chemiluminescence immunoassay (DiaSorin) was used, with 10 ng/L being taken as the upper limit of the normal range.

FNAB

All FNAB were performed at the Endocrine Unit by an endocrinologist with over 20 years of experience in thyroid nodule diagnosis and management, who used a 22-gauge needle [14]. At least two passes for each nodule were performed. Smear glass slides were air-dried or fixed with Cytolyt (Marlborough, MA, USA) and stained with May-Grunwald-Giemsa or Papanicolaou. All cytological samples were evaluated by the same pathologist with more than 10 years of experience in thyroid cytology; the results were reported according to the 2014 BTA classification [15]. The Thy 3a category was assigned when atypical features were present but not sufficient

to assign the specimen to any of the other categories. This category includes specimens with increased cellularity with small uniform follicular organization and scant colloid, and follicular cells with small nuclei and regularly distributed chromatin. The Thy 3f category was assigned when a follicular neoplasm was suspected, but did not present sufficient features for inclusion in the Thy 4 category (suspicious for malignancy). The Thy 3f category includes specimens with hyper-cellularity and absence of colloid, well-defined nests, rarely with overlapping nuclei, follicular cells with enlarged nuclei, sparse or irregularly distributed chromatin, rare prominent nucleoli and occasional mitoses. The Thy 3a and Thy 3f categories correspond to Bethesda category III (atypia of indeterminate significance/follicular lesion of indeterminate significance: AUS/FLUS) and Bethesda category IV (Follicular Neoplasm/Suspicious for Follicular Neoplasm: FN/SFN) neoplasms [16,17]. When surgery was performed, pathology examination was carried out on formalin-fixed, paraffin-embedded tissue in accordance with the World Health Organization guidelines [18] and more recent indications for encapsulated FvPTC without invasion and noninvasive follicular thyroid neoplasms with papillary-like nuclear features [19].

Molecular biology analysis

Once the adequacy of the sample had been checked (> 50% of neoplastic cells) and DNA extracted, BRAF and RAS mutations were investigated as previously reported [6].

Ultrasound assessment

The same physician validated all the conventional US examinations, which were carried out by means of a high-resolution device with a color Doppler module equipped with a linear probe working at 7.5 - 10 MHz (My Lab Five, Esaote Biomedica, Genoa, Italy). In accordance with US guidelines from Moon et al. [20], the following parameters were investigated: echogenicity vs. non-nodular tissue, presence or absence of a halo sign, presence or absence of micro-calcifications, and presence or absence of an inner nodular flow pattern. USE and CEUS examinations were performed as previously reported [3,21] at the Interventional Radiology Unit and validated by the same radiologist with more than 5 years' experience. From 2015 to 2016, semi-quantitative (strain) USE examinations were performed by means of a My Lab 70 XvG US machine (Esaote Biomedica); subsequently, quantitative (shear-wave) USE examinations were performed by means of a hand-held GE Logiq E9 US machine (GE Medical, Milwaukee, IL, USA). Both machines were equipped with probes working in the range of 7-15 MHz. CEUS images

were collected after injection of a bolus of 4.8 mL Sono Vue (Bracco, Milan, Italy).

Instrumental and Statistical analysis

In order to estimate the malignancy risk of each nodule with indeterminate cytology, an institutional cut-off obtained by means of cytological-histological correlation was applied and Receiver-Operating Characteristic (ROC) analysis was used for US, USE and CEUS [3,12,21]. After US, a score (from 0 to 5) was arbitrarily calculated for the indeterminate nodule, with one point being assigned for the presence of each of the following radiological findings: solid, hypo-echoic, micro-calcification, internal vascularization, and irregular shape. A score >2 was considered suspicious for malignancy [3,12]. With regard to semi-quantitative USE, the indeterminate nodule was considered suspicious when the strain index ELX 2/1 was greater than 1 [3,12]. For quantitative USE, the indeterminate nodule was considered suspicious when the shear-wave index was greater than 28 kPa [21]. USE methods changed during the study period; if both USE methods were available, the stiffness of the nodule was considered suspicious when all indexes were concordant. This information was assigned a score of 0 (= USE not suspicious) or 1 (= USE suspicious). After CEUS examination, a peak (P) index <1 and time-to-peak (TTP) index >1 were considered suspicious for malignancy. Changes in maximal diameter (increase or decrease) were arbitrarily considered significant when greater than 20% in comparison with the previous evaluation, according to the internal variability in measures [22].

Non-parametric tests were used to compare averages; the correlation coefficient (r) was calculated by means of Spearman's correlation (Sr) (Graph Pad 7.0 Software, San Diego, CA, USA). Data are reported as mean \pm Standard Error of Mean (SEM) if not otherwise reported. Significance was set at $P \leq 0.05$.

Results

Clinical data

Table 1 reports data on entry to this observational study. In the study population, the number of females was significantly higher than that of males ($P < 0.0001$); in the majority of subjects, the suspicious nodule was located in an MNG ($P < 0.0001$). Mean and median f-T4 and TSH values were in the normal range. USE showed an increase in strain in 31 (42%) of the nodules evaluated; both CEUS indexes were outside of our cut-off in the same nodules in 18 (27%) cases. When split according to the 2014 BTA classification, the number of Thy 3a

nodules was significantly ($P < 0.0001$) higher than that of Thy 3f nodules. (Table 1). When both USE and CEUS indexes were evaluable in the same nodule ($n=64$), all cut-off values were suspicious for malignancy in 6 nodules (9%). A major comorbidity was present in a few patients (lung cancer $n=2$, severe cardiac insufficiency $n=2$, renal transplant $n=1$, kidney cancer $n=1$).

FNAB Cytology

All but 3 nodules with indeterminate cytology underwent a new FNAB 1-3 months after the first evaluation. The second FNAB was not performed on account of lung cancer progression ($n=1$) and patient refusal ($n=2$). Figure 1 reports the results of the second cytological evaluation. In the majority of nodules, the result of the second FNAB was Thy 2 (benign; $n=43$; 51%), while in some nodules the second FNAB was inadequate (Thy 1; $n=11$; 13%). In 25 nodules (30%), the result of the second FNAB was unchanged, while a change in indeterminate subclass was observed in 5 nodules (6%); in 4 of these latter cases, the subclass changed from Thy 3a to Thy 3f, while in 1 case a Thy 3f nodule was reclassified as Thy 3a. At this time-point, a further FNAB was performed in 27 nodules. In the 2 patients with concomitant lung cancer, only observation was undertaken for thyroid disease. In 9 patients, surgery was decided upon either before or at the moment of scheduled FNAB. In 3 patients, a further FNAB was refused 12-24 months after the beginning of the protocol. The result of the new FNAB was inadequate in 5 nodules, benign in 14 ($n=1$ Thy 1c; $n=13$ Thy 2), and indeterminate in 8 ($n=4$ Thy 3a; $n=3$ Thy 3f).

Clinical and instrumental outcome

Two female patients with an MNG had US scores, USE strain and CEUS indexes above our institutional cut-off. In the first patient (69 years) the nodule (13 mm; US score 3) was Thy 3f on the 2 baseline FNABs; after 36 months of surveillance, it was Thy 1c on the 3rd FNAB, and at the last examination the US score and maximal diameter were unchanged. This nodule is still under observation. In the second patient (51 years) the nodule (31 mm; US score 4) was Thy 3a on the first baseline FNAB and Thy 2 on the second; after 6 months, it was unchanged in score and diameter. This patient was lost to follow-up.

Table 1: Some clinical baseline data of the 87 subjects with indeterminate nodules enrolled in the study.

			Significance
Sex, number (%)	Males	20 (23%)	P<0.0001
	Females	67 (77%)	
Age, years	Mean ± SD	59.1 ± 13.8	-
	Median (range)	62 (30 - 84)	
Diagnosis, number (%)	MNG	74 (85%)	P<0.0001
	1 UNG	13 (15%)	
f-T4, pmol/l	Mean ± SEM	14.9 ± 0.3	-
	Median (range)	14.5 (7.7 - 21.7)	
TSH, mIU/l	Mean ± SEM	1.75 ± 0.14	-
	Median (range)	1.50 (0.03 - 6.80)	
Semi-quantitative USE, ELX 2/1 index (2)	Mean ± SEM	1.30 ± 0.09	-
	Median (range)	1.10 (0.50 - 3.90)	
Quantitative USE, kPa (2)	Mean ± SEM	38.5 ± 3.0	-
	Median (range)	30 (5-128)	
CEUS, P index	Mean ± SEM	0.99 ± 0.02	-
	Median (range)	1.00 (0.53 - 1.40)	
CEUS, TTP index	Mean ± SEM	1.02 ± 0.05	-
	Median (range)	0.92 (0.51 - 3.60)	
FNAB, number (%)	Thy 3a	54 (62%)	P<0.0001
	4 Thy 3f	20 (23%)	
	Thy 3	13 (15%)	

(1) MNG = Multinodular Goiter; UNG = Uninodular Goiter.

(2) USE was performed in 74 patients, in 42 of whom it was semi-quantitative. Quantitative USE was performed in 69 patients. Semi-quantitative USE was not technically feasible in 2 patients.

(3) CEUS was available in 64 patients; 2 patients refused contrast injection.

(4) Significance was evaluated between Thy 3a and Thy 3f nodules

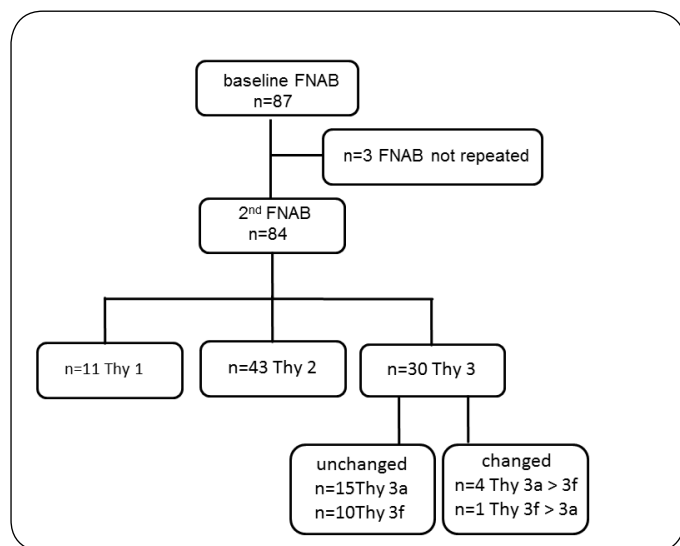


Figure 1: Changes in Thy classification according to the BTA from the 1st to the 2nd FNAB.

Over 6-36 months, surgery was performed in 9

nodules for various reasons (n=4 compressive symptoms and/or increase in volume, n= 2 positive RAS mutation or lack of DNA amplification for BRAF analysis; n=1 concomitant hyperthyroidism; n=1 a finding of Thy 3a in another nodule, and significant increase in diameter and US score). Malignancy (histology: minimally invasive FTC and concomitant micro-PTC) was found in only one nodule, while a contralateral micro-PTC was found in a benign nodule. In 3 patients, surgery was proposed after 6 months, owing to an increase in nodule size, and after 12 months, owing to an increase in US score and compressive symptoms; it was refused. Drop-out occurred after the 6-, 12-, and 24-month examinations in 3, 4, and 2 patients, respectively. The reasons were: n=1 withdrawal of consent, n=2 change in residence and n=6 unknown. One patient died of lung carcinoma after the 6-month examination. At the present time, the median follow-up is 18.9±1.4 months (median 12; range 6-36 months) and active surveillance is still ongoing in 69 nodules.

Figure 2 reports the maximal diameter of the nodules during the observation period and changes from the baseline to the last examination. No significant changes were observed between the baseline (median 21 mm; range 8-75 mm) and the last examination (median 22 mm; range 9-100 mm). A >20% decrease in maximal diameter was noted in 8 nodules and a >20% increase in 14 nodules. In the majority of nodules (75%) changes in maximal diameter were of 20% or less. The percentage change in the maximal diameter was unrelated to either the baseline diameter ($P=0.07$) or the length of follow-up ($P=0.1$).

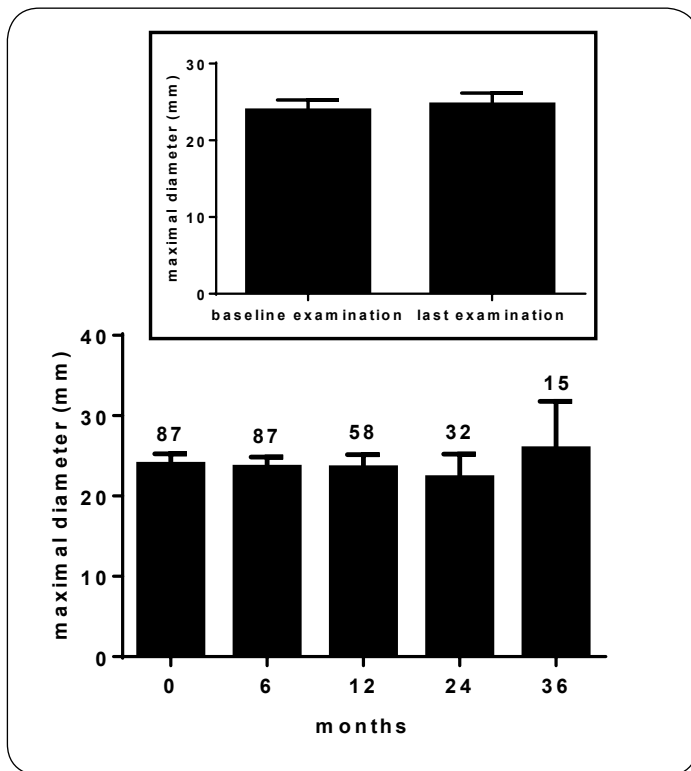


Figure 2: Changes in maximal diameter during the observation protocol in Thy 3 nodules according to the BTA classification. The number at the top of the column indicates the number of nodules evaluated at each experimental time. The insert shows the US score at the baseline and last examination. The P value yielded by Wilcoxon's test is reported.

Figure 3 reports the US scores recorded in nodules during the observation period and changes from the baseline (median 2; range 0-5) to the last examination (median 1; range 0-4). No significant changes were observed. A significant correlation was noted between the baseline US score and TPOAb titer ($n=70$; $rS -0.25$, $P=0.04$) and between the baseline US score and both pathological TTP index and P index on CEUS ($n=66$; $rS -0.33$, $P=0.01$). No correlations were observed between US score and

patient age, nodule diameter, baseline hormonal status or USE evaluation.

The overall rate of malignancy in nodules which underwent surgery after the beginning of the observation protocol was 17%. Two conflicting micro-PTCs were found in the patient with FTC and in a patient with follicular adenoma.

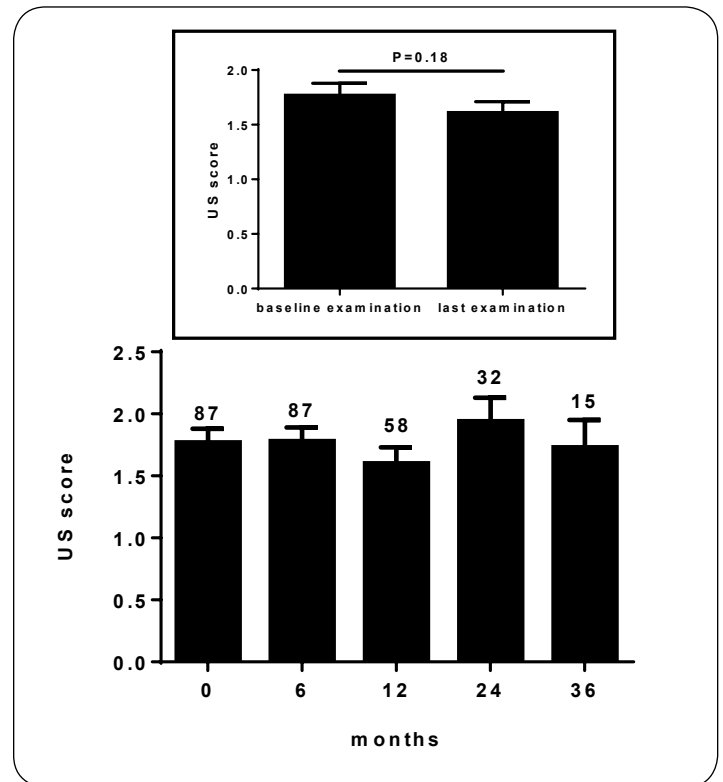


Figure 3: Changes in US score during the observation protocol in Thy 3 nodules according to the BTA classification. The number at the top of the column indicates the number of nodules evaluated at each experimental time. The insert shows the US score at the baseline and last examination.

Discussion

For years, cytopathologists and endocrinologists have used standardized systems to codify the thyroid cytology [2,15,16]. In our study, we utilized the 5-level BTA classification, which was updated in 2014 and is widely used in Europe [17]. In the BTA classification, results are stratified according to risk into categories that range from "probably absent" (Thy 2) to "highly probable" (Thy 5). The subclasses Thy 3a and Thy 3f have now been introduced in an effort to improve risk stratification in those classes defined as "indeterminate" (Thy 3), in which the potential for malignancy is uncertain [17]. Variable percentages of indeterminate results have been reported in the

literature. In a meta-analysis of 25,445 FNABs from eight studies which used the Bethesda System for Reporting Thyroid Cytopathology (BSRTC), indeterminate results were recorded in 20% of cases [16]. In that study, 10% of indeterminate lesions were assigned to the BSRTC III (AUS/FLUS) class, which is similar to the Thy 3a class, and 10% were assigned to the BSRTC IV (FN/SFN) class, which is similar to the Thy 3f class [16]. In a study of 3843 FNABs, Kakudo et al. [23] found 10% of indeterminate lesions. Rago et al. [24] found that 5% of lesions were Thy 3; on sub-classifying 1520 Thy 3 nodules, they assigned 77% to the Thy 3a class and 33% to the Thy 3f class. In our previous studies, the percentage of indeterminate lesions was 8-10% [12,14]; this percentage (9%) was confirmed in the series of FNABs considered in the present study. In our retrospective reassessment of Thy 3 nodules observed between 2011 and 2014 and reclassified according to the 2014 BTA into the two above-mentioned subclasses, the percentages of Thy 3a and Thy 3f nodules were 44% and 56%, respectively [12]. In the present study, by contrast, and in line with the data from Rago et al. [24], we observed a higher frequency of Thy 3a lesions than of Thy 3f lesions and of lesions that could not be sub-classified. Differences in the stratification of nodules into the different subclasses, both over time and among the various studies, may be explained by the progressive modification in the enrolment of patients for FNAB in the light of the indications provided in the literature [25] and by the growing experience of pathologists in sub-classifying indeterminate lesions.

A current indication to repeat FNAB in Thy 3a lesions and to surgically excise Thy 3f nodules is provided by the guidelines [5,13], although the current literature recommends that the indications of molecular biology be taken into account before proceeding to surgery [4,25]. Recently, in a 2017 review of the BSRTC, the risk of malignancy in BSRTC III lesions was estimated to be 6-18%, and that of BSRTC IV lesions 10-40% [2]. In our experience [12] of Thy 3 nodules with a documented correlation between cytology and histology, a greater risk of malignancy in Thy 3f nodules (14%) than in Thy 3a nodules (26%) was not confirmed. In our view, this finding allows an observational approach to be adopted in both subclasses of nodules with indeterminate cytology when calcitonin levels and molecular biology data are not indicative of an increased risk. A similar observation could be made on the basis of the findings reported by Deaver et al. [9], who analyzed 2019 FNABs over a period of 5 years, 11% of which were cases of BSRTC III and 4% were BSRTC IV. They found that the overall rate of malignancy

in lesions with BSRTC III cytology (both with and without surgery) was 10% (24% in surgically excised nodules), a substantially similar percentage to that observed in lesions with BSRTC IV cytology (with and without surgery): 13.8% (20% in surgically excised nodules) [9]. In our study, the rate of malignancy was therefore in line with the literature data [8-10,26,27]. The aim of the present prospective study was to avoid the immediate recourse to surgery in Thy 3 nodules. However, it only partially allows us to make a further contribution to the estimation of the malignant potential of Thy3 nodules, as malignancy has so far been found in 17% of cases.

Repeating FNAB now appears to be justified in all nodules with Thy 3 indeterminate cytology. It seems surprising that, in our study, the addition of new material to that yielded by the first FNAB was able to prompt cytological reclassification in many cases. Indeed, in some 51% of the cases reassessed, reclassification as Thy 2 meant the almost complete disappearance of the risk of malignancy. However, it also confirmed the limits of the technique, as 13% of the second FNABs proved non-diagnostic (Thy 1). The meaning of the shift from one subclass to another, which we observed in a more limited number (6%) of nodules, remains to be determined.

Similar observations can now be found in the literature. On cytological reassessment of 103 BSRTC III nodules and 25 BSRTC IV nodules, Rossi et al. [8] recorded benign cytology on the new FNAB in 45% and 32% of cases, respectively, with >10% of FNABs being non-diagnostic. Moreover, in 33 of 231 nodules classified as BSRTC III, Deaver et al. [9] observed a similar reduction in the risk of malignancy in 63% of cases following the repetition of FNAB. A similar reduction (30% of cases) was also observed by these authors in a limited number of nodules (10 of 80) initially classified as BSRTC IV [9]. In the present study, we did not observe any cytological upgrade following the second FNAB, a phenomenon that has been observed in only two lesions initially classified as BSRTC IV in previous studies [8,9]. However, Jooya et al. [28] reported an upgrade in 17% and 20% of BSRTC III and IV, respectively.

In assessing the risk of malignancy of nodules with indeterminate cytology, cost and the availability of molecular biology remain limiting factors of a technique that is aimed at reducing unnecessary surgery present data; [7,29]. Thus, the repetition of FNAB, together with the use of ancillary US techniques, could constitute an added value in the management of thyroid nodules. In a

previous study [3], we observed that USE and CEUS could be associated to conventional US in the assessment of Thy 3 nodules on FNAB. By correlating cytology with histology in nodules sub-classified as Thy 3a and Thy 3f on FNAB [12], we were able to establish institutional cut-offs; these were used in the present study in order to identify nodules in which the decision to undertake long-term observation should be reconsidered. In our view, however, these ancillary techniques for identifying malignant nodules can, as yet, play only a complementary role, for various reasons: the difficulty of comparing different USE techniques over time; the difficulty of interpreting their results, owing to their inconsistent acceptance by patients, and their cost in comparison with traditional US [21]. Furthermore, recent reviews of thyroid nodule management [25] and the most recent Italian guidelines on thyroid cancer [5] do not consider or recommend their routine use in clinical practice. In recent years, numerous studies have suggested that US can be used to stratify the risk of malignancy in nodules with indeterminate cytology [30-32]. For instance, in a study of 463 nodules that were indeterminate on FNAB (33% BSRTC III; 62% BSRTC IV) and which underwent histological examination, Valderrabano et al. [32] observed a variable rate of malignancy (from 0% to 56%) on stratifying the nodules according to the US risk classes of the American Thyroid Association [13]. US also seems to be indispensable in establishing the size threshold for FNAB [5,13] and in personalizing the management of indeterminate nodules after FNAB [32,33]. In our previous experience, too, a score arbitrarily calculated according to the specific US features proved useful in the stratification of risk [12]. In the present study, a suspicious US score was noted in 17% of the nodules assigned to observation. The US score proved to be correlated both with thyroid autoimmunity and with a suspicious CEUS. This finding is in agreement with the need for closer surveillance of thyroid nodules in the setting of chronic autoimmune thyroiditis [34,35] and with the potential utility of CEUS for diagnostic purposes [21].

In nodules with indeterminate cytology, literature data on the meaning of changes in size are scant. On 5-year follow-up US examination of 116 nodules, Rossi et al. [8] observed that the size of the nodule was unchanged in 75% of cases, had decreased in 11% and had increased in 14%. Deaver et al. [9] reported 46-62-month follow-up data on a limited number of cases, and observed that 76% of the nodules had remained unchanged in size, while 24% had increased. In our patient cohort, in which the mean follow-up has now reached 19 months (range 6-36 months), a significant variation in the maximum

Adv Clin Endo Met, 2(1): 75-85 (2019)

nodule diameter has been recorded in only 25% of nodules, with an increase in 16% of cases and a reduction in 9%. The role of nodule size and of its growth pattern is controversial. Nakamura et al. [36] have observed that, in nodules initially diagnosed as "adenomatous", growth is not pathognomonic of malignancy, while in "follicular neoplasms" an increase in nodule size should be considered suspicious. In an Italian prospective study of over 1500 nodules apparently benign on US and on FNAB, dimensional stability proved to be the most frequent finding, and size increase proved to be a poor predictor of malignancy [37]. Recently, in a series of BSRTC III nodules of sub-category A (with architectural atypia), Kim et al. [38] also observed that size increase over time did not constitute a predictor of malignancy. Thus, at the moment, it can be claimed that, in nodules with indeterminate cytology, US modifications, rather than the growth pattern, should be considered in prospective evaluations when observation alone is undertaken.

The present study has considerable limitations: a) it involved a small number of subjects; b) in most patients, the period of observation is still short; c) in those few patients for whom surgery was recommended during the course of the program, histological data are often missing, owing to the patient's refusal and/or deferment of surgery; d) use of the proposed ancillary USE and CEUS techniques was rendered difficult by methodological problems and their not infrequent refusal by patients. Finally, it should be pointed out that our selection of Thy 3 nodules, upstream of the assignment to observation, involves the use of a molecular biology technique that does not, as yet, perform as well [6] as those reported in the literature [7,29].

Conclusion

In conclusion, with regard to nodules with indeterminate cytology, we can foresee a similar scenario to that which is now envisioned in the case of PTC, in which active observation seems to be the choice of the future in low-risk cases with dimensions of less than 10-15 mm [39]. Thus, in our view, active surveillance can be proposed in cases of indeterminate cytology, both in the setting of Thy 3a and in that of Thy 3f, if the preliminary evaluation of calcitonin is negative, there are no compressive problems, molecular biology valuation is negative, the US score indicates low risk, the ancillary USE and CEUS techniques, taken together, do not add a further risk factor, the repetition of FNAB does not document an upgrade in the cytological class, and the patient consents.

References

1. Mihai R, Parker AJC, Roskell D, Sadler GP. One in four patients with follicular thyroid cytology (Thy3) has a thyroid carcinoma. *Thyroid*. 2009;19(1):33-37. Doi: <https://doi.org/10.1089/thy.2008.0200>
2. Cibas ES, Ali SZ. The 2017 Bethesda system for reporting thyroid cytopathology. *Thyroid*. 2017;27(11):1341-1346. Doi: <https://doi.org/10.1089/thy.2017.0500>
3. Giusti M, Campomenosi C, Gay S, et al. The use of semi-quantitative ultrasound elastosonography in combination with conventional ultrasonography and contrast-enhanced ultrasonography in the assessment of malignancy risk of thyroid nodules with indeterminate cytology. *Thyroid Res*. 2014;7(1):9. Doi: <https://doi.org/10.1186/s13044-014-0009-8>
4. de Koster EJ, de Geus-Oei L-F, Dekkers OM, et al. Diagnostic utility of molecular and imaging biomarkers in cytological indeterminate thyroid nodules. *Endocr Rev*. 2018;39(2):154-191. Doi: <https://doi.org/10.1210/er.2017-00133>
5. Pacini F, Basolo F, Bellantone R, et al. Italian consensus on diagnosis and treatment of differentiated thyroid cancer: joint statements of six Italian societies. *J Endocrinol Invest*. 2018;41(7):849-876. Doi: <https://doi.org/10.1007/s40618-018-0884-2>
6. Monti E, Bovero M, Mortara L, et al. BRAF mutations in an Italian regional population: implications for the therapy of thyroid cancer. *Int J Clin Endocrinol*. 2015;2015:1-7. Doi: <https://doi.org/10.1155/2015/138734>
7. Patel KN, Angell TE, Babiarz J, et al. Performance of a genomic sequencing classifier for the preoperative diagnosis of cytologically indeterminate thyroid nodules. *JAMA Surg*. 2018;153(9):817-824. Doi: <https://doi.org/10.1001/jamasurg.2018.1153>
8. Rossi M, Lupo S, Rossi R, et al. Proposal for a novel management of indeterminate thyroid nodules on the basis of cytopathological subclasses. *Endocrine*. 2017;57(1):98-107. Doi: <https://doi.org/10.1007/s12020-016-1105-4>
9. Deaver KE, Haugen BR, Pozdeyev N, Marshall CB. Outcomes of Bethesda categories III and IV thyroid nodules over 5 years and performance of the Afirma gene expression classifier: a single-institution study. *Clin Endocrinol (Oxf)*. May 2018. Doi: <https://doi.org/10.1111/cen.13747>
10. Khalil AB, Dina R, Meeran K, et al. Indeterminate thyroid nodules: a pragmatic approach. *Eur Thyroid J*. 2018;7(1):39-43. Doi: <https://doi.org/10.1159/000484600>
11. Lee DJ, Xu JJ, Brown DH, et al. Determining patient preferences for indeterminate thyroid nodules: observation, surgery or molecular tests. *World J Surg*. 2017;41(6):1513-1520. Doi: <https://doi.org/10.1007/s00268-017-3887-9>
12. Giusti M, Massa B, Balestra M, et al. Retrospective cytological evaluation of indeterminate thyroid nodules according to the British Thyroid Association 2014 classification and comparison of clinical evaluation and outcomes. *J Zhejiang Univ Sci B*. 2017;18(7):555-566. Doi: <https://doi.org/10.1631/jzus.B1600075>
13. Haugen BR, Alexander EK, Bible KC, et al. 2015 American thyroid association management guidelines for adult patients with thyroid nodules and differentiated thyroid cancer: the American thyroid association guidelines task force on thyroid nodules and differentiated thyroid cancer. *Thyroid*. 2016;26(1):1-133. Doi: <https://doi.org/10.1089/thy.2015.0020>
14. Sidoti M, Marino G, Resmini E, et al. The rational use of fine needle aspiration biopsy (FNA) in diagnosing thyroid nodules. *Minerva Endocrinol*. 2006;31(2):159-172.
15. BTA (British Thyroid Association) Guidelines for the management of thyroid cancer. Royal College of Physicians, London. 2014.
16. Bongiovanni M, Spitale A, Faquin WC, Mazzucchelli L, Baloch ZW. The Bethesda system for reporting thyroid cytopathology: a meta-analysis. *Acta Cytol*. 2012;56(4):333-339. Doi: <https://doi.org/10.1159/000339959>
17. Perros P, Boelaert K, Colley S, et al. BTA (British Thyroid Association) Guidelines for the management of thyroid cancer. *Clin Endocrinol*. 2014;81(s1):1-122. Doi: <https://doi.org/10.1111/cen.12515>
18. De Lellis R, Willimas E. Thyroid and parathyroid tumors. In: de Lellis RA, Lloyd RV, Heitz PV, Eng C, eds. *World Health Organization Classification of Tumours. Pathology & Genetics of Tumours of Endocrine Organs*. Lyon: JARC Press. 2004:49-97.
19. Haugen BR, Sawka AM, Alexander EK, et al. American thyroid association guidelines on the management of thyroid nodules and differentiated thyroid cancer task force review and recommendation on the proposed renaming of encapsulated follicular variant papillary thyroid carcinoma without invasion to noninvasive follicular thyroid neoplasm with papillary-like nuclear

- features. *Thyroid*. 2017;27(4):481-483. Doi: <https://doi.org/10.1089/thy.2016.0628>
20. Moon W-J, Baek JH, Jung SL, et al. Ultrasonography and the ultrasound-based management of thyroid nodules: consensus statement and recommendations. *Korean J Radiol*. 2011;12(1):1-14. Doi: <https://www.ncbi.nlm.nih.gov/pubmed/21228935>
 21. Gay S, Schiaffino S, Santamarena G, et al. Role of strain elastography and shear-wave elastography in a multiparametric clinical approach to indeterminate cytology thyroid nodules. *Med Sci Monit*. 2018;24:6273-6279. Doi: <https://doi.org/10.12659/MSM.909870>
 22. Massaro F, Vera L, Schiavo M, et al. Ultrasonography thyroid volume estimation in hyperthyroid patients treated with individual radioiodine dose. *J Endocrinol Invest*. 2007;30(4):318-322. Doi: <https://doi.org/10.1007/BF03346299>
 23. Kakudo K, Kameyama K, Hirokawa M, Katoh R, Nakamura H. Subclassification of follicular neoplasms recommended by the Japan thyroid association reporting system of thyroid cytology. *Int J Endocrinol*. 2015;2015:938305. Doi: <https://doi.org/10.1155/2015/938305>
 24. Rago T, Scutari M, Latrofa F, et al. The large majority of 1520 patients with indeterminate thyroid nodule at cytology have a favorable outcome, and a clinical risk score has a high negative predictive value for a more cumbersome cancer disease. *J Clin Endocrinol Metab*. 2014;99(10):3700-3707. Doi: <https://doi.org/10.1210/jc.2013-4401>
 25. Durante C, Grani G, Lamartina L, Filetti S, Mandel SJ, Cooper DS. The diagnosis and management of thyroid nodules: a review. *JAMA*. 2018;319(9):914-924. Doi: <https://doi.org/10.1001/jama.2018.0898>
 26. Duick DS, Klopper JP, Diggans JC, et al. The impact of benign gene expression classifier test results on the endocrinologist-patient decision to operate on patients with thyroid nodules with indeterminate fine-needle aspiration cytopathology. *Thyroid*. 2012;22(10):996-1001. Doi: <https://doi.org/10.1089/thy.2012.0180>
 27. Wu JX, Young S, Hung ML, et al. Clinical factors influencing the performance of gene expression classifier testing in indeterminate thyroid nodules. *Thyroid*. 2016;26(7):916-922. Doi: <https://doi.org/10.1089/thy.2015.0505>
 28. Jooya A, Saliba J, Blackburn A, et al. The role of repeat fine needle aspiration in the management of indeterminate thyroid nodules. *J Otolaryngol Head Neck Surg*. 2016;45(1): 51. Doi: <https://doi.org/10.1186/s40463-016-0164-0>
 29. Nabhan F, Porter K, Lupo MA, Randolph GW, Patel KN, Kloos RT. Heterogeneity in positive predictive value of RAS mutations in cytologically indeterminate thyroid nodules. *Thyroid*. 2018;28(6):729-738. Doi: <https://doi.org/10.1089/thy.2017.0635>
 30. Jeong SH, Hong HS, Lee EH, Cha JG, Park JS, Kwak JJ. Outcome of thyroid nodules characterized as atypia of undetermined significance or follicular lesion of undetermined significance and correlation with Ultrasound features and BRAF(V600e) mutation analysis. *AJR Am J Roentgenol*. 2013;201(6):W854-860. Doi: <https://doi.org/10.2214/AJR.12.9901>
 31. Yoon JH, Lee HS, Kim E-K, Moon HJ, Kwak JY. Anomogram for predicting malignancy in thyroid nodules diagnosed as atypia of undetermined significance/ follicular lesions of undetermined significance on fine needle aspiration. *Surgery*. 2014;155(6):1006-1013. Doi: <https://doi.org/10.1016/j.surg.2013.12.035>
 32. Valderrabano P, McGettigan MJ, Lam CA, et al. Thyroid nodules with indeterminate cytology: utility of the american thyroid association sonographic patterns for cancer risk stratification. *Thyroid*. 2018;28(8):1004-1012. Doi: <https://doi.org/10.1089/thy.2018.0085>
 33. Choi YJ, Baek JH, Shin JH, et al. Web-based thyroid imaging reporting and data system: Malignancy risk of atypia of undetermined significance or follicular lesion of undetermined significance thyroid nodules calculated by a combination of ultrasonography features and biopsy results. *Head Neck*. 2018;40(9):1917-1925. Doi: <https://doi.org/10.1002/hed.25173>
 34. Kim ES, Lim DJ, Baek KH, et al. Thyroglobulin antibody is associated with increased cancer risk in thyroid nodules. *Thyroid*. 2010;20(8):885-891. Doi: <https://doi.org/10.1089/thy.2009.0384>
 35. Boi F, Minerba L, Lai ML, et al. Both thyroid autoimmunity and increased serum TSH are independent risk factors for malignancy in patients with thyroid nodules. *J Endocrinol Invest*. 2013;36(5):313-320. Doi: <https://www.ncbi.nlm.nih.gov/pubmed/22931861>
 36. Nakamura H, Hirokawa M, Ota H, Kihara M, Miya A, Miyauchi A. Is an increase in thyroid nodule volume a risk factor for malignancy? *Thyroid*. 2015;25(7):804-811. Doi: <https://doi.org/10.1089/thy.2014.0567>
 37. Durante C, Costante G, Lucisano G, et al. The

natural history of benign thyroid nodules. *JAMA*. 2015;313(9):926-935. Doi: <https://doi.org/10.1001/jama.2015.0956>

38. Kim M, Jeon MJ, Han M, et al. Tumor growth rate does not predict malignancy in surgically resected thyroid nodules classified as Bethesda category III with architectural atypia. *Thyroid*. 2019;29(2):216-221. Doi: <https://doi.org/10.1089/thy.2018.0366>
39. Tuttle RM, Fagin JA, Minkowitz G, et al. Natural history and tumor volume kinetics of papillary thyroid cancers during active surveillance. *JAMA Otolaryngol Head Neck Surg*. 2017;143(10):1015-1020. Doi: <https://doi.org/10.1001/jamaoto.2017.1442>



Copyright: © **Giusti et al.** This is an Open Access article distributed under the terms of the Creative Commons Attribution License, which permits unrestricted use, distribution, and reproduction in any medium, provided the original work is properly cited.